

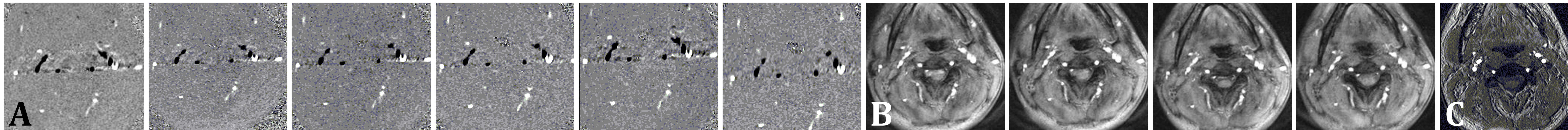
# AN MRI-COMPATIBLE LEG EXERCISE DEVICE FOR ASSESSING CEREBRAL BLOOD FLOW RESPONSES TO EXERCISE

KATHERINE LAKE, HENRY HU, JACOB STANGL, KELSI BJORKLUND

CLIENT: WILLIAM SCHRAGE, PHD

ADVISOR: MICHAEL TOEPKE, PHD

DEPARTMENT OF BIOMEDICAL ENGINEERING, UNIVERSITY OF WISCONSIN – MADISON



**Figure 1: MRI Scan Series**  
In Series A the carotid and vertebral arteries are shown in black and the images provide velocity data. In Series B, the carotid and vertebral arteries are shown in white and the images provide data on magnitude and anatomical information. Image C was taken prior to exercise while the patient was at rest.

## ABSTRACT

Our client, Dr. William Schrage, specializes in exercise physiology and vascular biology. He is currently interested in researching changes in blood flow and blood velocity to the brain during exercise. It is believed that blood flow to the brain increases during exercise<sup>1</sup>. An MRI scan allows researchers to clearly observe the carotid and vertebral arteries and determine the blood velocity and flow. We designed a cost effective and non-ferromagnetic exercise device that increased the heart rate to 120bpm. The design utilizes the motion of a bicycle wheel and keeps the head and neck steady for the duration of the scan. Our final device has been fabricated and tested; minimal movement artifact in MRI images demonstrates the device's usability in future studies.

## INTRODUCTION

Traditionally, transcranial Doppler ultrasound is utilized to measure blood velocity and flow, but ultrasound devices create limitations to use; only one vessel or artery can be observed at a time and dense bone can impede the ultrasound signal and produce unclear images<sup>2</sup>. MRI imaging allows researchers to capture more detail and observe the flow and velocity in several arteries simultaneously. One device designed to increase a patient's heart rate is currently being marketed, but it requires a patient to exercise before being inserted in to the MRI<sup>3</sup>. Additionally, the marketed device is prohibitively high in cost, which limits its use in research.

Our client requested that we develop a device that allows a patient to exercise while undergoing an MRI scan. Blood velocity and flow can be accurately and precisely calculated from clear MRI images<sup>2</sup>. Exercise increases the heart rate, so effects of increased blood velocity and flow can be easily observed in a patient with an exercise-induced increased heart rate.

## DESIGN CRITERIA


- Non-ferromagnetic materials
- Must increase heart rate to 120-130bpm for five minutes
- Comfortable to use by patients of varying fitness levels
- Operable by patients of heights 5'4" to 6'4"
- Must minimize head and neck movement during exercise
- Maximum width of 24" to fit on to the MRI bed
- Must be portable and easily removed from the MRI.

## REFERENCES:

1. Ide, K., & Secher, N.H. (2000). Cerebral blood flow and metabolism during exercise. *Prog. Neurobiol.* 61(4).
2. Essig, M. G. (2009). *Doppler ultrasound*. Retrieved April 27, 2011, from <http://www.webmd.com/a-to-z-guides/doppler-ultrasound>.
3. Lode B.V. - products. (2008). Retrieved 03/08, 2011, from [http://www.lode.nl/en/products/mri\\_ergometer\\_pedal](http://www.lode.nl/en/products/mri_ergometer_pedal).
4. Dahl, A., Russel, D., Nyberg-Hansen, R., Rootwelt, K., & Mowinkel, P. (1994). Simultaneous assessment of vasoreactivity using transcranial doppler ultrasound and cerebral blood flow in healthy subjects. *Journal of Cerebral Blood Flow and Metabolism*, 14(6), 974-975-981.

## FINAL DESIGN

### Overall Structure



**Figure 2: The Final Design.** The knee braces, flywheel, triangular supporting structure, and the connecting straps.

### Adjustable Knee Brace:

- Plastic buckles have a maximum load of 100 lb
- Four plastic buckles were incorporated onto the design in order to increase the maximum loading of the brace



**Figure 3:** The knee brace and attachment mechanism.



**Figure 4: The Flywheel**  
Brass bolts were added to increase the weight and inertia.

### Flywheel

- Base board and supporting structure consists of wood and brass screws
- Plastic flywheel with PVC axle and side arms



**Figure 5: The Triangular Supporting Structure**  
Aluminum beams and brass bolts were used to construct the sides.

### Triangular supporting structure:

- Used to direct forces along the vertical axis.
- 2x4 wooden beams were used as baseboards
  - Beams have a 60° angle from the horizontal plane
  - Structure height 27 inches

## FUTURE WORK

- Create concrete flywheel to increase fluidity of motion
- Modify pulley cords to produce constant velocity of flywheel.
- Create low-friction bed surface to reduce bed to foot friction.
- Apply breaking mechanism in order to increase required work.
- Modify flywheel in order to produce one-directional motion.

## TESTING & RESULTS



**Figure 6: The Vertebral and Carotid Arteries**  
A volume composite view of the major neck arteries.

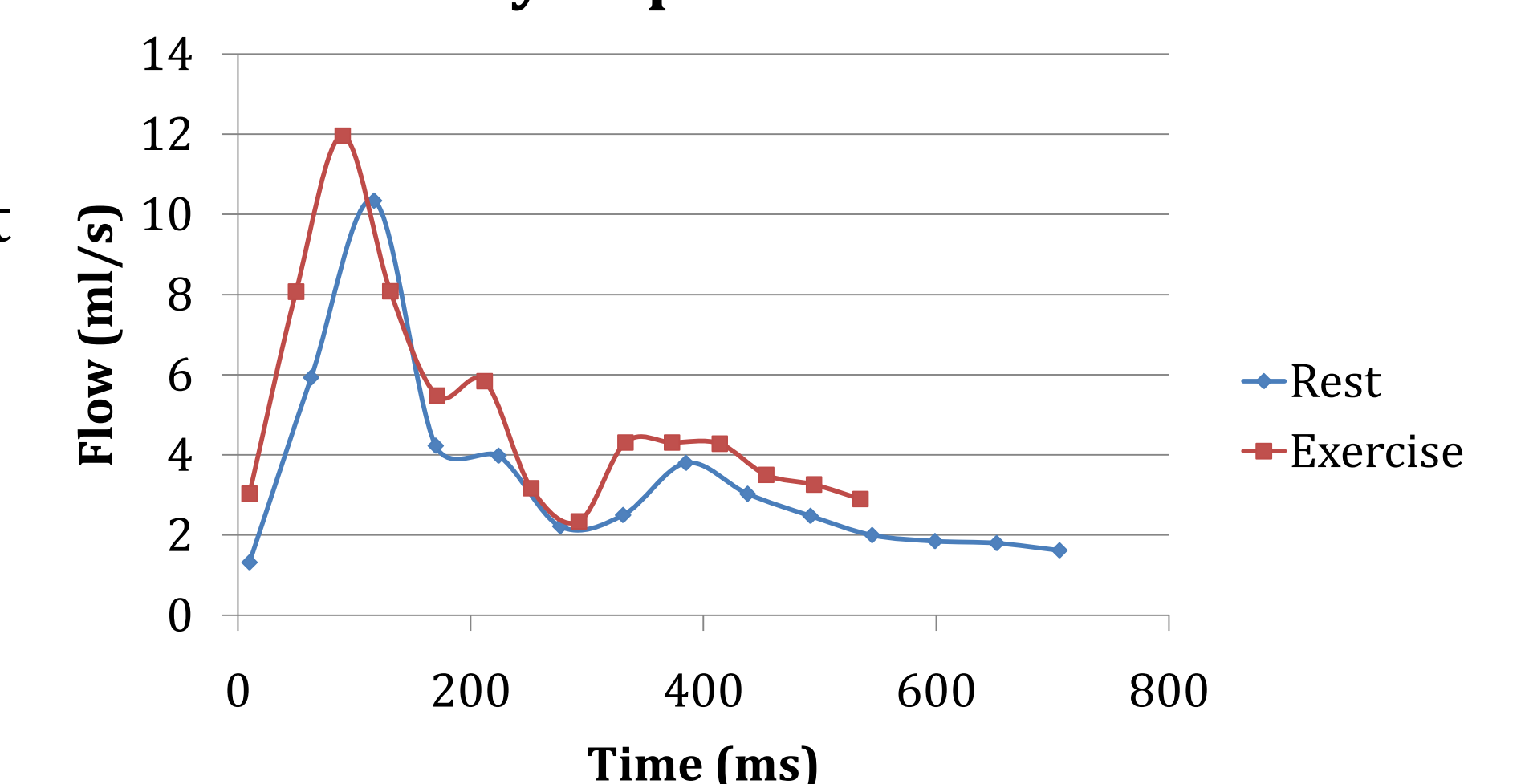
Patient	Height	Maximum Heart Rate (bpm)	Time to Increase (Min:Sec)
1	5'6"	120	5:30
2	5'10"	118	4:20
3	5'11"	115	3:30

**Figure 7: Maximum Heart Rate and Time Required to Achieve Increased Heart Rate**

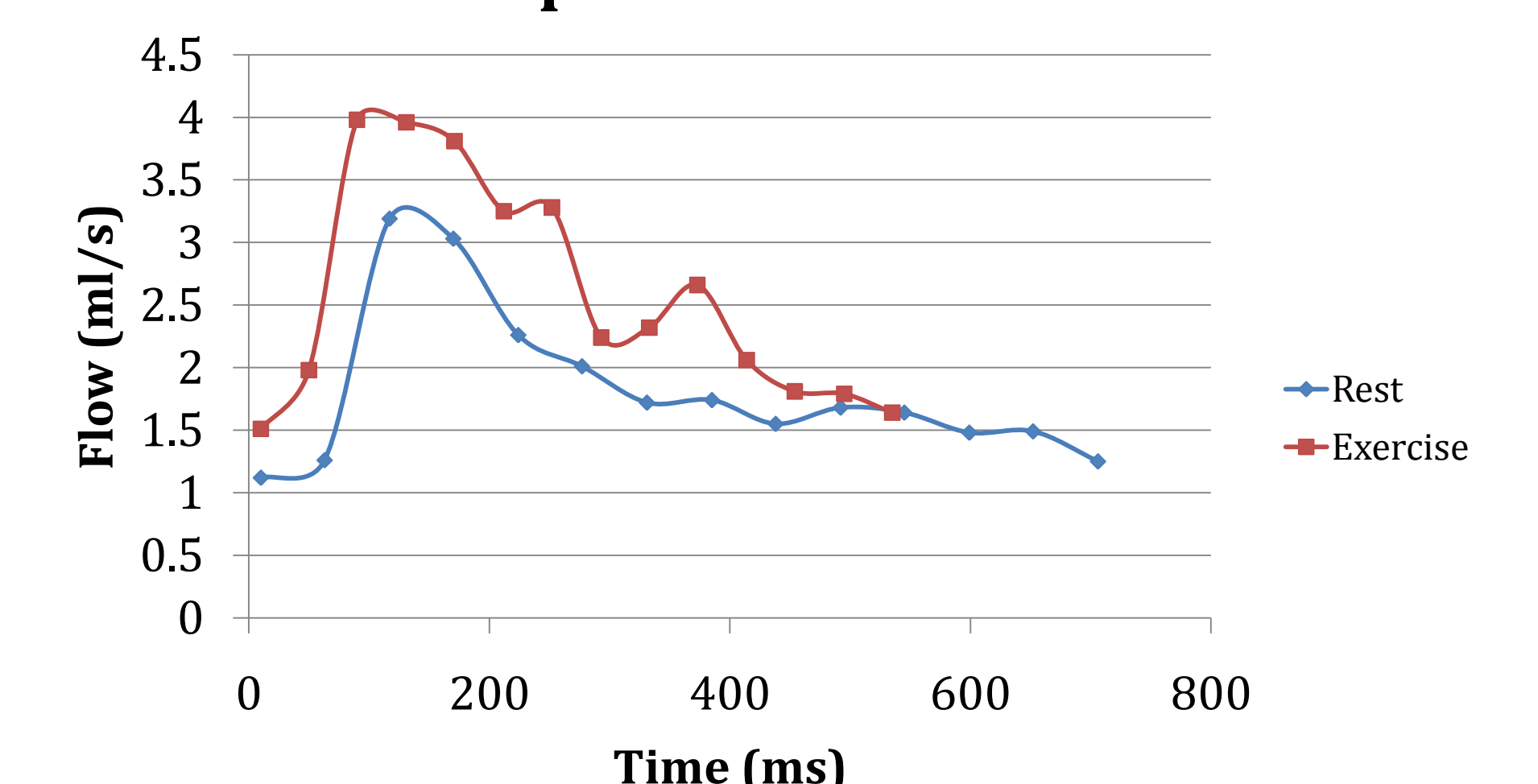
The data collected from Patient 3 was analyzed and it was determined that an average 22% increase in blood flow occurred through the left and right posterior and anterior carotid arteries and the left and right vertebral arteries. Transcranial Doppler ultrasound suggests increases of 10%-30% in middle cerebral artery velocity during times of increased heart rate, which is consistent with the observed 22% increase in blood flow<sup>4</sup>.

**Figure 8 and 9:** Increased blood flow was observed when Patient 3 exercised. The graph shows one cardioid cycle; an increased heartbeat during exercise is indicated by the decreased amount of time one full cardioid cycle requires.

### Blood Flow in Anterior Carotid Left Artery Dependent on Time



### Blood Flow in Left Vertebral Artery Dependent on Time



Three patients of different heights used the device to exercise while inserted in the MRI machine. Pulse oximetry monitoring was used to determine heart rate and the time each patient required to achieve a steady working heart rate was recorded.

Patient 3 underwent an MRI scan while exercising to determine the extent to which movement artifact would occur. Several MRI technicians analyzed the scans and determined that head movement during exercise was minimal and blood flow and velocity analysis could be performed on the images produced.

## ACKNOWLEDGEMENTS

- Dr. William Schrage
- Dr. Alejandro Roldán-Alzate
- Dr. Oliver Wieben
- Dr. Michael Toepke
- Dr. Kreg Gruben
- Mr. John Harrell